

RESEARCH

Open Access



# An early experience of lumbopelvic fixation techniques at Alexandria University

Islam Sorour<sup>1,2\*</sup> , Mohamed Abd Elbary<sup>1</sup>, Ahmed Rabie<sup>1</sup> and Abdelrahman Magdy Elhabashy<sup>1</sup>

## Abstract

**Background:** The aim of lumbopelvic fixation is to obtain a solid fusion across the lumbosacral junction. There are many indications for lumbopelvic fixation, namely, spinal deformity in cases requiring long segment fusion, pelvic obliquity, pseudarthrosis at the lumbosacral junction, infection or osteolytic tumors, and pathologic fractures. The classical iliac screws should be contained within the iliac bone but have some disadvantages: excessive soft tissue dissection needed for accurate insertion, screw prominence with patient discomfort, and usually, a side connector is needed to connect the iliac screws to the rest of the construct. Lumbopelvic fixation by insertion of S2 alar-iliac (S2AI) screws was recently described to overcome these disadvantages. In this study, the authors present the initial results for the evaluation of lumbopelvic fixation through the insertion of S2AI screws in 19 consecutive patients operated in the neurosurgery department at Alexandria University.

**Objective:** The aim of the study was to evaluate the efficacy and complications of lumbopelvic fixation through the use of S2 alar-iliac screws.

**Methods:** The authors conducted a retrospective cohort study of data collected from the database of patients who underwent lumbopelvic fixation through the insertion of S2AI screws from 2016 to 2019 at a single institution.

**Results:** There were 19 patients indicated for lumbopelvic fixation, operated by modern instrumentation systems using lumbar pedicle screws and S2 alar-iliac screws. There were 14 females and 5 males. The mean age at the time of the operation was  $38.6 \pm 19.4$  years with a range from 11 to 65 years. There was a total of 37 S2AI screws, screw diameter was 7mm in all cases regardless of age, and the length of the screws ranged from 50 mm in a young female patient (11 years) to 90 mm in an old male patient (60 years). Two screws were inserted per patient except in one case with congenital scoliosis due to the bad bone quality and the multiple iatrogenic wrong paths. Postoperative VAS score for back pain was greatly improved in all patients after the first 6 months of follow-up from  $8 \pm 1.5$  to  $3.5 \pm 1.2$  (paired  $t$ -test = 11.182,  $P < 0.001$ ). All patients had a good spinal range of motion to maintain normal daily activities without any significant restrictions after the first 3 months of follow-up. Immediate postoperative radiological follow-up had revealed 2 cases of posterior pelvic breaches and one case with anterior pelvic breach but without clinical manifestations with no need for revision. Two cases of unilateral screw breakout were observed after the first 6 months of follow-up. Removal of screws after the first 6 months was done in one patient with spondylodiscitis due to the unresolved infection and screw pullout.

**Conclusion:** The insertion of S2AI screws is an effective technique for lumbopelvic fixation with a relatively low rate of complications. Pelvic breaches are the commonest complications encountered during the insertion of S2AI screws, although no significant clinical morbidities were reported.

**Keywords:** Lumbopelvic fixation, S2 alar-iliac screws, Iliac screws

\* Correspondence: [i\\_sorour08@alexmed.edu.eg](mailto:i_sorour08@alexmed.edu.eg)

<sup>1</sup>Neurosurgery Department, Alexandria University, Alexandria, Egypt

<sup>2</sup>Alexandria, Egypt

## Introduction

The main aim of lumbopelvic fixation is to obtain a solid construct across the lumbosacral junction. The main indications of lumbopelvic fixation include the following: spinal deformity in cases requiring long segment fusion and in cases with high pelvic obliquity, pseudarthrosis, infections or tumors at the lumbosacral region associated with bone loss, and pathologic fractures [1, 2]. Classically, the starting point for pelvic screw insertion lies close to the posterior inferior iliac spine and should be contained within the boundaries of the thick iliac bone and has been shown to obtain a stable lumbopelvic construct [3]. However, lumbopelvic fixation through the use of the classical iliac screws has some disadvantages: excessive soft tissue dissection is needed for accurate insertion, soft tissue irritation and patient discomfort associated with the prominence of the classical iliac screws, and finally, the usual need of side connectors to connect the iliac screws to the remainder of the construct [4, 5]. In order to avoid most of these complications, a novel way for lumbopelvic fixation has evolved [6, 7]. Chang et al. first described lumbopelvic fixation by insertion of S2 alar-iliac (S2AI) in 2009 [8]. Although the freehand techniques for the insertion of most spinal implants have

been evaluated with encouraging results [9, 10], however, a paucity of data exists with regard to the evaluation of the free-hand technique for S2 alar-iliac screw insertion [6]. In this study, the authors present the initial results for evaluation of lumbopelvic fixation through the insertion of S2AI screws in 19 consecutive patients operated in the neurosurgery department at Alexandria University.

## Methods

The authors conducted a retrospective cohort study of data collected from the database of patients who underwent lumbopelvic fixation through the insertion of S2AI screws from 2016 to 2019 at a single institution.

The aim was to evaluate the efficacy and complications of lumbopelvic fixation through the use of the S2 alar-iliac screws. There were 19 patients indicated for lumbopelvic fixation, operated by modern instrumentation systems using lumbar pedicle screws and S2 alar-iliac screws. There were 14 females and 5 males. The mean age at the time of the operation was  $38.6 \pm 19.4$  years with a range from 11 to 65 years. The indications for lumbopelvic fixation were the following: 7 cases of spondylolisthesis (3 cases of isthmic spondylolisthesis and 4

**Table 1** The demographic, clinical, and radiological data of the 19 patients

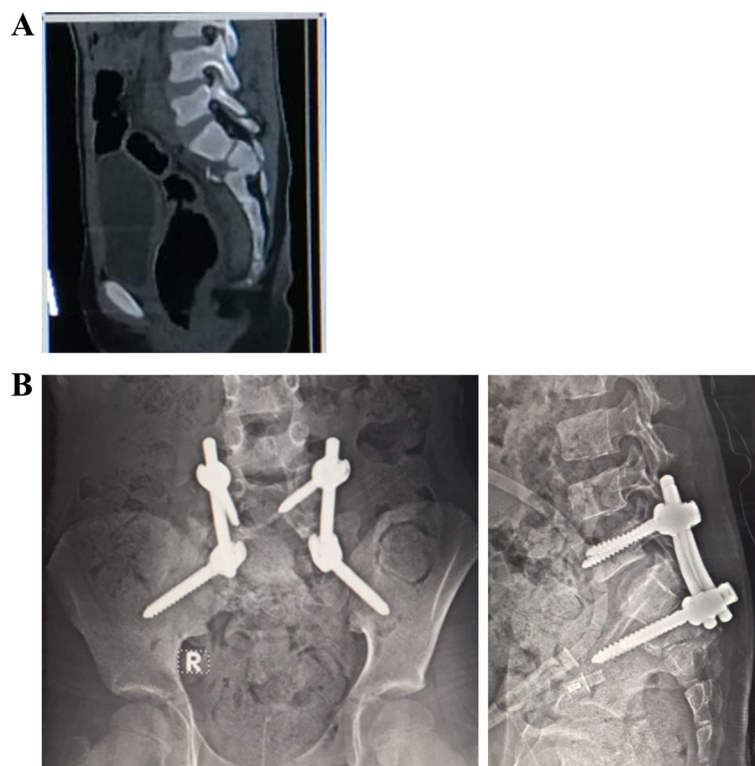
Name	Age	Sex	Follow-up (ms)	Indication	Screw length	Pre VAS score	6 ms post VAS score	Radiological complications
1	41	F	12	Isthmic spondylolisthesis	75mm	9	2	RT screw breakout
2	42	F	12	Sacral tumor	80mm	9	2	No
3	11	F	12	Sacral fracture	50mm	9	3	No
4	65	M	12	L5-S1 discitis (postoperative)	80mm	10	5	LT screw pullout and rod loosening
5	12	F	18	AIS	75mm	5	3	No
6	20	F	18	AIS	80mm	6	3	No
7	14	M	18	AIS	75mm	5	2	No
8	17	F	12	Sacral fracture	80mm	10	3	No
9	27	M	12	L5-S1 discitis (spontaneous)	80mm	10	4	Unilateral anterior breach
10	60	M	12	Degenerative scoliosis	90mm	8	4	LT screw breakout
11	55	F	9	Degenerative scoliosis	80	9	5	No
12	55	F	12	Congenital scoliosis	75mm	9	2	Unilateral posterior breach
13	13	F	12	Isthmic spondylolisthesis	75mm	7	3	Unilateral posterior breach
14	40	F	18	Isthmic spondylolisthesis	85	7	4	No
15	58	F	18	Degenerative spondylolisthesis	75mm	8	4	No
16	49	F	18	Degenerative spondylolisthesis	75mm	7	4	No
17	35	F	18	Degenerative spondylolisthesis	75mm	8	5	No
18	60	F	9m	Degenerative spondylolisthesis	75	8	3	No
19	60	M	12	Degenerative retrolisthesis	80mm	8	6	No

cases of degenerative L5-S1 spondylolisthesis), 6 cases of scoliosis (1 case of congenital lumbar hemivertebra, 2 case of degenerative scoliosis, and 3 cases of adolescent idiopathic scoliosis), 2 cases of fracture sacrum, 2 cases of L5-S1 discitis, one case of degenerative retrolisthesis, and one case of sacral tumor (Table 1). The main indications for pelvic fixation in the 4 cases of degenerative spondylolisthesis were the poor bone quality (osteoporosis) in the affected patients with the need for fusion of multiple motion segments down to the sacrum. The three cases with isthmic spondylolisthesis were associated with high degree spondylolisthesis. The presence of a long construct extending down to the sacrum in scoliosis cases was the main indication to include the pelvis in the construct. The eroded S1 sacral body was the main indication of pelvic fixation in the 2 cases of L5-S1 discitis and the case diagnosed with the sacral tumor. There was one case of spontaneous L5-S1 discitis in a drug addict adult, while the second case was an old diabetic male suffering from postoperative L5-S1 discitis following an operation for lumbosacral decompression and fusion from L3 down to the sacrum. The case of postoperative discitis was complaining of persistent severe low back pain for 3 years after the initial surgery. The radiological investigations had revealed the signs of

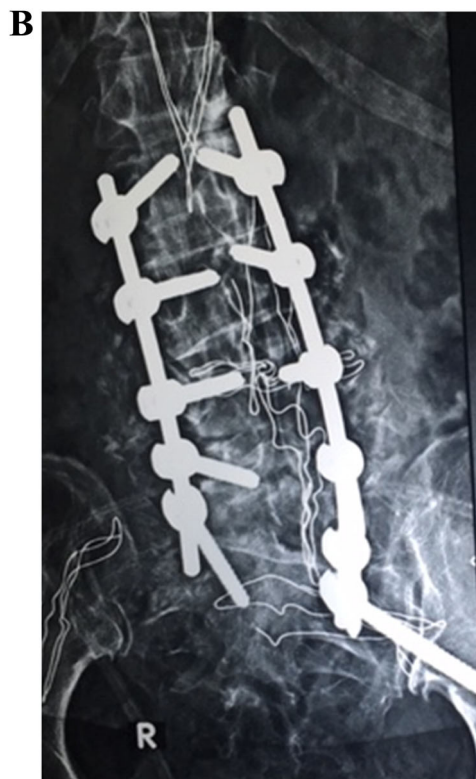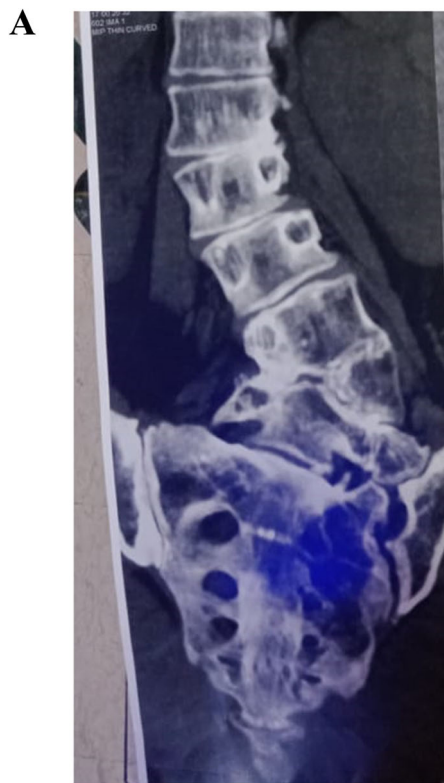
L5-S1 discitis in association with a hardware failure in the form of sacral screws pulled out. The case with the degenerative retrolisthesis was complaining of severe low back pain and bilateral sciatica following an operation for lumbosacral decompression and fusion from D11-L4. The patient was complaining of back pain and sciatica for 1 year after the initial surgery. The radiological investigations had revealed L4-5 instability with retrolisthesis with the necessity to extend the fusion down to the sacrum and pelvis. All patients were operated by senior spine surgeons for lumbopelvic fixation via the insertion of S2-alar iliac screws which were connected with the remaining lumbar pedicle screws via the same rods (Fig. 1). Postoperative radiological evaluation was done by PXR and CT scans. Evaluation of the patients was done via clinical and radiological follow-up for at least 9 months and up to 18 months.

#### Outcome measures

Spinal range of motion and VAS score for back pain were used for clinical evaluation of the involved patients. Radiological assessment was obtained via plain X-ray AP and lateral views of the instrumented segments in addition to the CT scanning for more detailed evaluation.



**Fig. 1** **a** A sagittal midline CT image of the lumbosacral spine region showing a sacral fracture in an 11-year-old female. **b** Three months postoperative AP and lateral plain X-ray images of the lumbosacral spine region showing the lumbopelvic fixation through the use of a 50-mm S2 alar-iliac screw after decompression of the sacral canal



**Fig. 2 a** Preoperative LSS CT scan showing a case of congenital scoliosis in a 55-year-old female patient with a left-sided hemivertebra in between L4 and L5. **b** Immediate postoperative plain X-rays after removal of the hemivertebrae and partial correction with lumbopelvic fixation at one side

Data were fed to the computer and analyzed using the IBM SPSS software package version 20.0. (Armonk, NY: IBM Corp). The Kolmogorov-Smirnov was used to verify the normality of distribution of variables. Paired *t*-test was assessed for comparison between two periods for normally distributed quantitative variables. Significance of the obtained results was judged at the 5% level.

An approval from the research ethics committee of the Faculty of Medicine, Alexandria University [serial number 0304468], was obtained in November 2019.

### Surgical technique

After subperiosteal dissection of the paraspinal muscles attached to the lumbosacral spine, lumbosacral pedicle screws were inserted by the traditional fluoroscopy-guided methods. The entry point for insertion of S2 alar-iliac screws was revealed by more distal dissection along the sacrum, and it should be in line with S1 pedicle screws or just lateral at any point between S1 and S2 dorsal foramina. It was easier to insert the S2 alar-iliac screws from the contralateral side by initial drilling of the entry point followed by tapping using a 2-mm blunt-tipped pedicle probe. The pedicle probe was advanced towards the anterior inferior iliac spine crossing the hard surface of the sacroiliac joint with the curve of the probe directed dorsally to avoid anterior perforation of the pelvic wall. Once the hard surface of the sacroiliac joint was reached at a depth of about 50 mm in adults, the pedicle probe was then removed, and assessment of the osseous channel by a blunt ball-tipped flexible sound was done. The assessment should include the four osseous walls beside the floor. The pedicle probe was reinserted once more with the curve of the probe directed ventrally and advanced towards the anterior inferior iliac spine in a smooth consistent manner. AP view by C-arm was a guide to avoid breaching into the sciatic notch or the acetabulum. Once the pedicle probe reached the thick iliac bone above the sciatic notch, it was removed, and the osseous channel was reassessed once again to make sure a secure path for the screw and to assess the

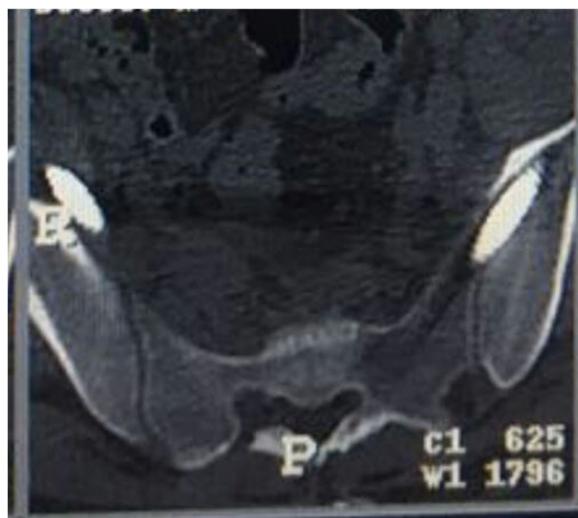**Table 2** Comparison between preoperative and postoperative VAS score ( $n = 19$ )

VAS score	Pre	Post 6 months	<i>t</i>	<i>p</i>
Mean $\pm$ SD.	8 $\pm$ 1.5	3.5 $\pm$ 1.2	11.182*	<0.001*
Median (Min.–Max.)	8 (5 – 10)	3 (2 – 6)		

*t*, paired *t*-test; *p*, *p* value for comparing between pre and post 6 months

\*Statistically significant at  $p \leq 0.05$





**Fig. 3** Postoperative axial CT scan showing an anterior pelvic breach in a patient operated for lumbopelvic fixation due to L5-S1 discitis

desired screw length which usually ranges from 70 to 90 mm in adults. The screw was then inserted within the desired path, and its position could be confirmed by C arm. A rod was inserted to attach the S2AI screw to the remainder of the lumbosacral construct without the need of any side connector.

## Results

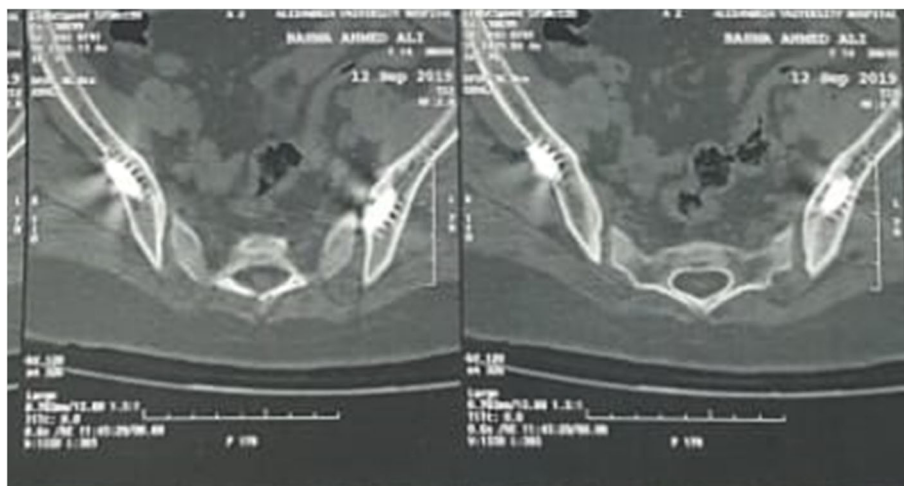
There were 19 patients indicated for lumbopelvic fixation, operated by modern instrumentation systems using lumbar pedicle screws and S2 alar-iliac screws. There were 14 females and 5 males. The mean age at the time of the operation was  $36.4 \pm 19.4$  years with a range from 11 to 65 years. There was a total of 37 S2AI

screws, screw diameter was 7mm in all cases regardless the age, and the length of the screws ranged from 50 mm in a young female patient (11 years) to 90 mm in an old male patient (60 years) (Table 1). All the S2AI screws were polyaxial. Two Screws were inserted per patient except in one case with congenital scoliosis due to the bad bone quality and the presence of multiple iatrogenic wrong paths (Fig. 2).

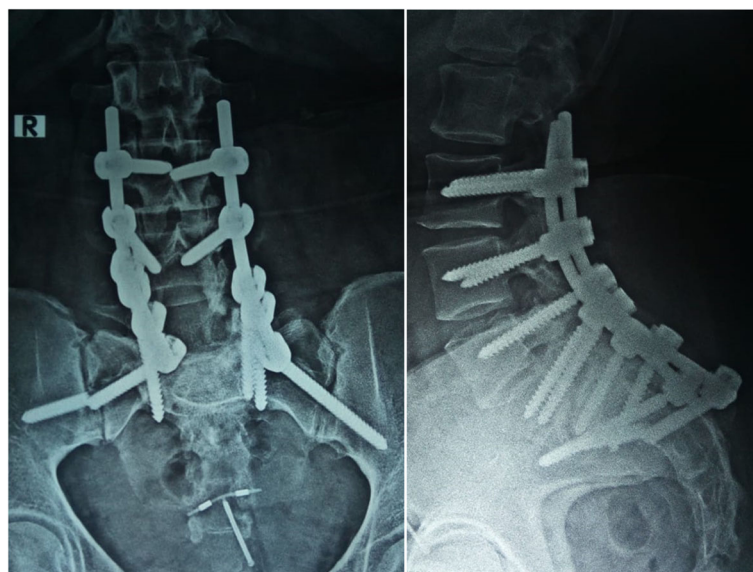
Postoperative VAS score for back pain was greatly improved in all patients after the first 6 months of follow-up from  $8 \pm 1.5$  to  $3.5 \pm 1.2$  (paired  $t$ -test=11.182,  $P < 0.001$ ) (Table 2). All patients had a good spinal range of motion to maintain normal daily activities without any significant restrictions after the first 3 months of follow-up. No complications related to the screw prominence were recorded. Radiological follow-up had revealed 2 cases of posterior pelvic breaches and one anterior pelvic breach but without clinical manifestations with no need for revision (Figs. 3, 4). Two cases of unilateral screw breakout were observed after the first 6 months of follow-up (Fig. 5). Removal of the screws after the first 6 months was done in one patient with spondylodiscitis due to unresolved infection with pelvic screw pull out and rod loosening (Fig. 6).

## Discussion

Surgical fusion across the lumbosacral region is still considered a surgical challenge despite the availability of modern techniques of spinal fixation. The sacrum has a complex anatomy and poor bone quality; in addition, there is a unique biomechanical force across the lumbosacral junction. These factors greatly contribute to the high failure and complication rates associated with fusion across the lumbosacral junction [11–13].



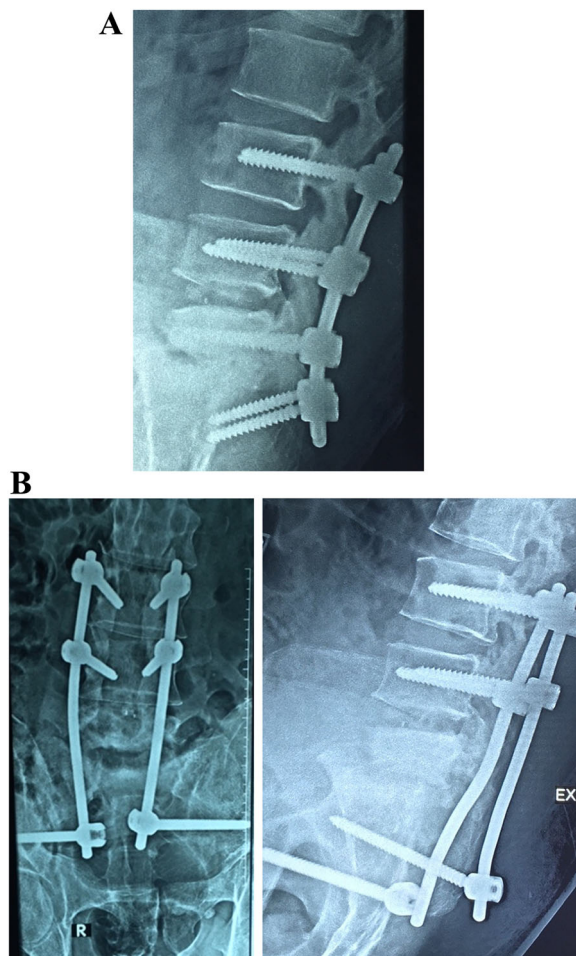
**Fig. 4** Postoperative axial CT scan showing a posterior pelvic breach in a patient operated for lumbopelvic fixation due to congenital pars defect and L5-S1 spondylolisthesis



**Fig. 5** Six months postoperative AP and lateral plain X-ray images of the lumbosacral spine region showing Rt pelvic screw failure and break out in a patient operated for lumbopelvic fixation for correction of high-grade isthmic spondylolisthesis (note the vertically oriented superior sacral endplate with a resultant high-degree sacral slope)

Augmentation of lumbosacral fusion through the use of pelvic screws is needed to decrease the high failure and complication rate associated with the lumbosacral fixation techniques [12, 13]. Classically, the traditional iliac screws have been used effectively to augment lumbosacral fusion. However, there are some drawbacks that may limit the use of the traditional iliac screws: the excessive soft tissue dissection needed before the screw insertion, the need for a side connector to connect the iliac screws to the rest of the lumbosacral construct, and finally, the usual complain of postoperative patient discomfort associated with the screw prominence [4, 5, 13]. As a result of these disadvantages, many spine surgeons are discreet to use the classical iliac screws, and hence, the more recent use of the S2 alar-iliac screws [8]. Many authors have demonstrated better clinical and radiological results with the use of the S2AI screws. Sponseller et al. reported few complications with the use of the S2AI screw technique [14]. Ilyas et al. also reported better results with S2AI screws in adult and pediatric populations compared with the traditional iliac screw insertion [5]. The freehand technique for insertion of S2 alar iliac screws has recently been described and evaluated by few authors [6, 15]. This technique has the advantage of easily accessible anatomical landmarks: the entry point that is easily inspected without excessive soft tissue dissection, and the target point, the anterior inferior iliac spine, which is easily palpable. Although does not completely obviate the use of intraoperative fluoroscopy, this technique could lead to less exposure to harmful radiation for both the surgeon and the patient,

in addition to less operative time with better outcome [6, 16]. Based on our results, we report that the use of S2 alar-iliac screws is an efficient method for lumbopelvic fixation. Our series revealed 3 major radiological complications, namely, pelvic breaches, screw breakout, and screw pull out (Figs. 3, 4, 5, and 6). There were 2 breaches in the posterior pelvic wall (10.5%) and one breach through the anterior pelvic wall (5.3%) but without any clinical morbidity. O'Brien et al. reported a breach rate of 15% through the posterior pelvic wall muscles in a cadaveric study [17]. Shillingford et al. found a rate of 7% breach through the posterior pelvic wall and only 1% breach through the anterior wall but without any major complications [6]. Inferior violation into the sciatic notch was not encountered in our series. This type of violation may result in serious complications related to the superior gluteal neurovascular bundle and the sciatic nerve as they pass through the sciatic notch [18]. Our results had revealed 2 cases of unilateral screw breakout (10.5%) within the first year of follow-up. This was observed in patients with high degree isthmic spondylolisthesis and degenerative scoliosis. None of these patients has been returned to the operative room for re-do surgery, as none of them experienced a significant change in back pain VAS score. The screw breakout complications may be due to the use of the polyaxial S2AI screws rather than the monoaxial screws. Another possible cause for the screw failure is the acute angle between the screw head and the screw shaft of the S2AI screws. Also, in the case operated for correction of high-grade isthmic spondylolisthesis, the high degree of the



**Fig. 6** **a** Three years postoperative lateral view plain X-ray image of a 65-year-old diabetic male patient operated for lumbosacral fixation, showing the signs of L5-S1 discitis and hardware failure in the form of sacral screw pull out. **b** Six months postoperative plain X-ray AP and lateral views of the lumbosacral spine region after removal of the old hardware and insertion of a new hardware from L3 down to the pelvis escaping the L5 and S1 bodies due to the bad bone quality and the excessive osteolytic reaction associated with the infective process. Note the pull out of the pelvic screw and rod loosening

sacral slope may increase the biomechanical stresses across the region of the lumbosacral junction with more stresses on the pelvic screws (Fig. 5). Although there might be a relation between the postoperative sagittal balance and the S2AI screw failure, but to date, there is limited data evaluating the sacropelvic fixation using the S2AI screws in terms of postoperative sagittal balance outcomes [5, 13, 19]. In 2015, Guler et al. had reported a multicenter review of 45 patients who underwent sacroiliac fixation with S2AI screws (44%) or the classical iliac screws (56%). The authors reported a failure rate of 35% for the S2AI group, while the failure rate among the iliac screw group was only 12%. This difference was statistically significant. The authors acknowledged this high

**Table 3** Statistical analysis of the clinical and radiological data of the studied cases ( $n = 19$ )

	No. (%)
<b>Sex</b>	
Male	5 (26.3%)
Female	14 (73.7%)
<b>Age</b>	
Mean $\pm$ SD.	38.6 $\pm$ 19.4
Median (Min.–Max.)	41 (11–65)
<b>Follow-up (months)</b>	
Mean $\pm$ SD.	13.9 $\pm$ 3.3
Median (Min.–Max.)	12 (9–18)
<b>Indication</b>	
Sacral fracture	2 (10.5%)
Sacral tumor	1 (5.3%)
Degenerative listhesis	4 (21.2%)
Degenerative scoliosis	2 (10.5%)
Degenerative retrolisthesis	1 (5.3%)
Congenital fracture pars	3 (15.8%)
Congenital scoliosis	1 (5.3%)
L5-S1 discitis	2 (10.5%)
AIS	3 (15.8%)
<b>Radiological complications</b>	
No	13 (68.4%)
Screw breakout	2 (10.5%)
Screw pull out and rod loosening	1 (5.3%)
Unilateral anterior breach	1 (5.3%)
Unilateral posterior breach	2 (10.5%)

failure rate to the use of the polyaxial S2AI screws as there was no failure reported with the use of the monoaxial S2A screws. They also reported the acute angle between the screw head and the screw shaft as a potential cause of failure [13]. Screw pull out and rod loosening were observed in one patient (5.9%) with spondylodiscitis and unresolved infection. This particular patient was operated for removal of the whole construct due to pseudarthrosis after the first 6 months of follow-up (Table 3).

#### Study limitations

The small numbers of the cohort group with a relatively short period of follow-up are the main limitations of this study.

#### Conclusion

The insertion of S2AI screws is an effective technique for lumbopelvic fixation with a relatively low rate of complications. Pelvic breaches are the commonest



complications encountered during the insertion of S2AI screws, although no significant clinical morbidities were reported.

#### Abbreviations

S2AI: S2 alar-iliac; AIS: Adolescent idiopathic scoliosis

#### Acknowledgements

Not applicable.

#### Authors' contributions

IS designed the study and wrote the initial manuscript. MAE assisted in the final preparation of the manuscript. AEE participated in the final revision of the manuscript and added two more cases operated by the same technique. All authors have contributed to this study and approved the final version of the manuscript.

#### Funding

This study was not funded by any source.

#### Availability of data and materials

All data used are available from the corresponding author on request.

#### Declarations

##### Ethics approval and consent to participate

An approval from the research ethics committee of the Faculty of Medicine, Alexandria University [serial number 0304468], was obtained in November 2019. Furthermore, being a retrospective study, patients' consents for participation were not applicable.

##### Consent for publication

Not applicable.

##### Competing interests

The authors declare that they had no competing interests.

Received: 21 December 2019 Accepted: 15 April 2021

Published online: 21 June 2021

#### References

1. Jones CB, Sietsema DL, Hoffmann MF. Can lumbopelvic fixation salvage unstable complex sacral fractures? *Clin Orthop Relat Res*. 2012;470(8):2132–41.
2. Suk SI, Chung ER, Lee SM, Lee JH, Kim SS, Kim JH. Posterior vertebral column resection in fixed lumbosacral deformity. *Spine (Phila Pa 1976)*. 2005;30(23):E703–10.
3. Kuklo TR, Bridwell KH, Lewis SJ, Baldus C, Blanke K, Iffrig TM, et al. Minimum 2-year analysis of sacropelvic fixation and L5-S1 fusion using S1 and iliac screws. *Spine (Phila Pa 1976)*. 2001;26(18):1976–83.
4. Jain A, Hassanzadeh H, Strike SA, Menga EN, Sponseller PD, Kebaish KM. Pelvic fixation in adult and pediatric spine surgery: historical perspective, indications, and techniques: AAOS exhibit selection. *J Bone Joint Surg Am*. 2015;97(18):1521–8.
5. Ilyas H, Place H, Puryear A. A comparison of early clinical and radiographic complications of iliac screw fixation versus S2 alar iliac (S2AI) fixation in the adult and pediatric populations. *J Spinal Disord Tech*. 2015;28(4):E199–205.
6. Shillingford JN, Laratta JL, Tan LA, Sarpong NO, Lin JD, Fischer CR, et al. The free-hand technique for S2-alar-iliac screw placement: a safe and effective method for sacropelvic fixation in adult spinal deformity. *J Bone Joint Surg Am*. 2018;100(4):334–42.
7. Yilmaz E, Abdul-Jabbar A, Tawfik T, Iwanaga J, Schmidt CK, Chapman J, et al. S2 alar-iliac screw insertion: technical note with pictorial guide. *World Neurosurg*. 2018;113:e296–301.
8. Chang TL, Sponseller PD, Kebaish KM, Fishman EK. Low profile pelvic fixation: anatomic parameters for sacral alar-iliac fixation versus traditional iliac fixation. *Spine (Phila Pa 1976)*. 2009;34(5):436–40.
9. Kim YJ, Lenke LG, Bridwell KH, Cho YS, Riew KD. Free hand pedicle screw placement in the thoracic spine: is it safe? *Spine (Phila Pa 1976)*. 2004;29(3):333–42 discussion 42.

10. Ct K, Maher PC, Levine NB, Kurokawa R. Prospective evaluation of thoracic pedicle screw placement using fluoroscopic imaging. *J Spinal Disord Tech*. 2004;17(3):206–14.
11. Yoshihara H. Surgical options for lumbosacral fusion: biomechanical stability, advantage, disadvantage and affecting factors in selecting options. *Eur J Orthop Surg Traumatol*. 2014;24(Suppl 1):S73–82.
12. Kebaish KM. Sacropelvic fixation: techniques and complications. *Spine (Phila Pa 1976)*. 2010;35(25):2245–51.
13. Guler UO, Cetin E, Yaman O, Pellise F, Casademut AV, Sabat MD, et al. Sacropelvic fixation in adult spinal deformity (ASD); a very high rate of mechanical failure. *Eur Spine J*. 2015;24(5):1085–91.
14. Sponseller PD, Zimmerman RM, Ko PS, Pull Ter Gunne AF, Mohamed AS, Chang TL, et al. Low profile pelvic fixation with the sacral alar iliac technique in the pediatric population improves results at two-year minimum follow-up. *Spine (Phila Pa 1976)*. 2010;35(20):1887–92.
15. Park JH, Hyun SJ, Kim KJ, Jahng TA. Free hand insertion technique of S2 sacral alar-iliac screws for spino-pelvic fixation: technical note, acadaveric study. *J Korean Neurosurg Soc*. 2015;58(6):578–81.
16. Kim YJ, Bridwell KH, Lenke LG, Cho KJ, Edwards CC, 2nd, Rinella AS. Pseudarthrosis in adult spinal deformity following multisegmental instrumentation and arthrodesis. *J Bone Joint Surg Am*. 2006;88(4):721–8.
17. O'Brien JR, Yu WD, Bhatnagar R, Sponseller P, Kebaish KM. An anatomic study of the S2 iliac technique for lumbopelvic screw placement. *Spine (Phila Pa 1976)*. 2009;34(12):E439–42.
18. Mattei TA, Fassett DR. Combined S-1 and S-2 sacral alar-iliac screws as a salvage technique for pelvic fixation after pseudarthrosis and lumbosacropelvic instability: technical note. *J Neurosurg Spine*. 2013;19(3):321–30.
19. Mazur MD, Ravindra VM, Schmidt MH, Brodke DS, Lawrence BD, Riva-Cambrian J, et al. Unplanned reoperation after lumbopelvic fixation with S-2 alar-iliac screws or iliac bolts. *J Neurosurg Spine*. 2015;23(1):67–76.

#### Publisher's Note

Springer Nature remains neutral with regard to jurisdictional claims in published maps and institutional affiliations.

**Submit your manuscript to a SpringerOpen<sup>®</sup> journal and benefit from:**

- Convenient online submission
- Rigorous peer review
- Open access: articles freely available online
- High visibility within the field
- Retaining the copyright to your article

Submit your next manuscript at ► [springeropen.com](https://www.springeropen.com)