


RESEARCH

Open Access



Computer-guided cranioplasty using ultra-high molecular weight polyethylene patient-specific implants: a case series

Mariam S. K. Abdelwahed^{1*} , Mamdouh S. Ahmed¹, Ahmed S. Kamel Abdelwahed² and Mohamed M. Aziz³

Abstract

Introduction Cranioplasty is the surgical correction of a cranial defect. Three-dimensional software designs have allowed patient-specific single-step cranial reconstruction for neuroprotection and cosmesis. Ultra-high molecular weight polyethylene for partial or total bone replacement has been recently introduced as a promising material for cranioplasty. The objectives of this study are to evaluate the complications and esthetic results concerning the use of ultra-high molecular weight polyethylene patient-specific implants in craniectomy patients.

Methods We report a series of nine patients with cranial defects from a previous craniectomy, or patients eligible for simultaneous craniectomy and cranioplasty via computer designed ultra-high molecular weight polyethylene patient-specific implants. We have analyzed the complications and cosmetic outcomes over a course of six months.

Results None of the cases developed infection, extra/subdural hematoma, cerebrospinal fluid leak, or implant failure. Three cases had postoperative sequelae: The first patient had mild postoperative seroma which subsided after medical therapy and compression, the second showed wound breakdown due to tumor metastasis and recurrence but did not necessitate implant removal, while the third sequela was a subgaleal hematoma which was aspirated, and the patient healed uneventfully afterward. Esthetic results were highly satisfactory in 75% of the patients (good patient acceptance without touch-ups).

Conclusion Ultra-high molecular weight polyethylene is in all respects suitable for primary and secondary cranioplasty, combined with computer-aided manufacturing–computer-aided design techniques, excellent esthetic and functional results were achieved. However, proper preoperative planning is important, and we recommend further prospective studies with larger number of patients followed up for longer periods for better assessment.

Keywords Cranioplasty, Cranial reconstruction, Neurosurgery, UHMWP, PSI

Introduction

Cranioplasty, as a procedure, carries functional and esthetic importance, and a consensus is still to be reached among the profession

regarding what constitutes an ideal graft material [1–5]. The standard of care in Egypt, to this date, is still titanium meshes and polymethyl methacrylate (PMMA) reconstruction through intraoperative free hand adaptation.

Three-dimensional software designs coupled with synthetic new materials allowed patient-specific single-step cranial reconstruction for neuroprotection and cosmesis. Ultra-high molecular weight polyethylene (UHMWP), a biocompatible semicrystalline polymer and the gold standard for prosthetic joints [6, 7], was recently introduced for cosmetic neuroprotection of cranial defects

*Correspondence:

Mariam S. K. Abdelwahed
mariam.kamel@dentistry.cu.edu.eg

¹ Oral and Maxillofacial Surgery Department, Cairo University, Cairo, Egypt

² Department of Neurosurgery, Cairo University, Cairo, Egypt

³ Department of Neurosurgery, Ain Shams University, Cairo, Egypt

[8, 9]. Due to its excellent mechanical and physical properties.

The International Standards Organization (ISO) defines UHMWP as having a molecular weight of at least 1 million g/mole and a degree of polymerization of 36,000 [10]. In addition to having the highest fracture resistance known in the market [11], it exhibits direct bonding to bone [12], lubricity, low cytotoxicity [13] and is light in weight which, fit the biological and mechanical requirements for its use as a prosthetic cranioplasty implant. This study aims to report our experience with computer-guided UHMWP patient-specific implants (PSI) regarding overall complication rates and cosmetic patient satisfaction.

Materials and methods

After receiving institutional review board approval from the Ethics committee of scientific research, Faculty of Dentistry-Cairo University, this study has included nine patients with cranial defects from a previous craniectomy, or patients eligible for simultaneous craniectomy and cranioplasty and excluded patients showing any signs of active infection, hydrocephalus or were unfit for general anesthesia between 2020 and 2022 in Nasser Institute Hospital for Research and Treatment, Cairo, Egypt.

Cranial plate computer-aided design (CAD) and computer-aided manufacturing (CAM)

Preoperative high-resolution multislice computed tomography (CT) 1.0-mm-thick slices were obtained for each patient, and the digital imaging and communication in medicine (DICOM) files were analyzed using specialized medical software. The maxillofacial surgeon then rebuilt the affected side and designed the prosthesis through mirror imaging of the intact side with a chamfer to avoid any sinking into the skull. The final project, after being reviewed by the neurosurgeon Nasser

institute hospital for research and treatment, gets converted to a standard tessellation language (STL) file and is exported to the computerized numerical control (CNC) milling company. Finally, the maxillofacial surgeon checks the printed prosthesis against the defect template, orients, and prefixes the titanium microplates oriented to it before it gets double packed and sterilized at 121° immediately before surgery Fig. 1. When simultaneous resection and reconstruction were planned during a single-stage surgery, the maxillofacial surgeon did virtual preoperative resection on the 3D model upon consent by the neurosurgeon for proper safety margin assessment on the 2D imaging and printed a prefabricated custom-made cutting guide in resin material, as shown in Fig. 2a.

Intraoperative procedure

With subjects under general anesthesia, different cranial skin flaps were chosen on an individual patient basis. The cranial defect area with circumferential sound bone borders was exposed by incising the pericranium around the defect, as shown in Fig. 3. In resection cases, the margins defined in the presurgical planning were outlined with the help of resection template, as shown in Fig. 2d. Shrinking of the pericranium and dura into the confines of the defect was done with resorbable sutures. The UHMWP PSIs were then checked for fit, and when necessary, adjustments were carried out using an acrylic Egg shape cutting bur. Vicryl tuck-up suturing of the dura was occasionally done to prevent extradural collections, as shown in Figs. 2f and 5c. Finally, fixation of the UHMWP PSI to the surrounding bone was done with titanium microplates and screws—a subgaleal suction drain emplaced as needed before closure in layers and crepe bandage wrapped for compression, as shown in Fig. 3.

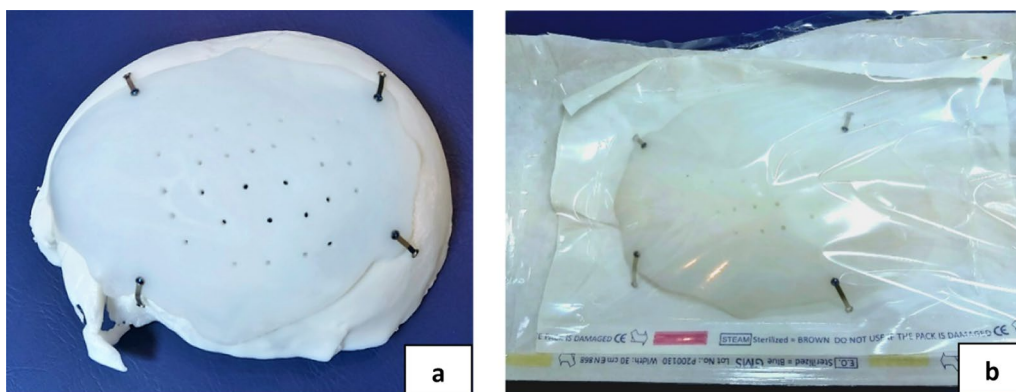


Fig. 1 a Prebending and fixing of microplates on the defect model. b Double packing the cranial plate prior to sterilization

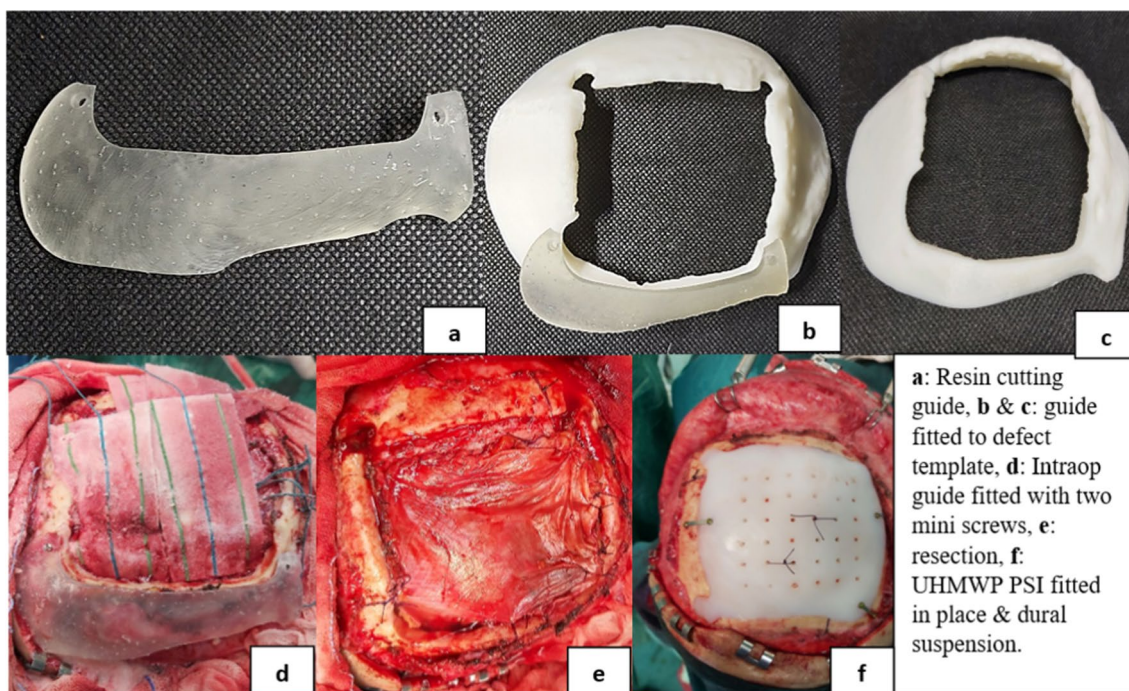


Fig. 2 A case of recurrent meningioma with resection template and reconstruction

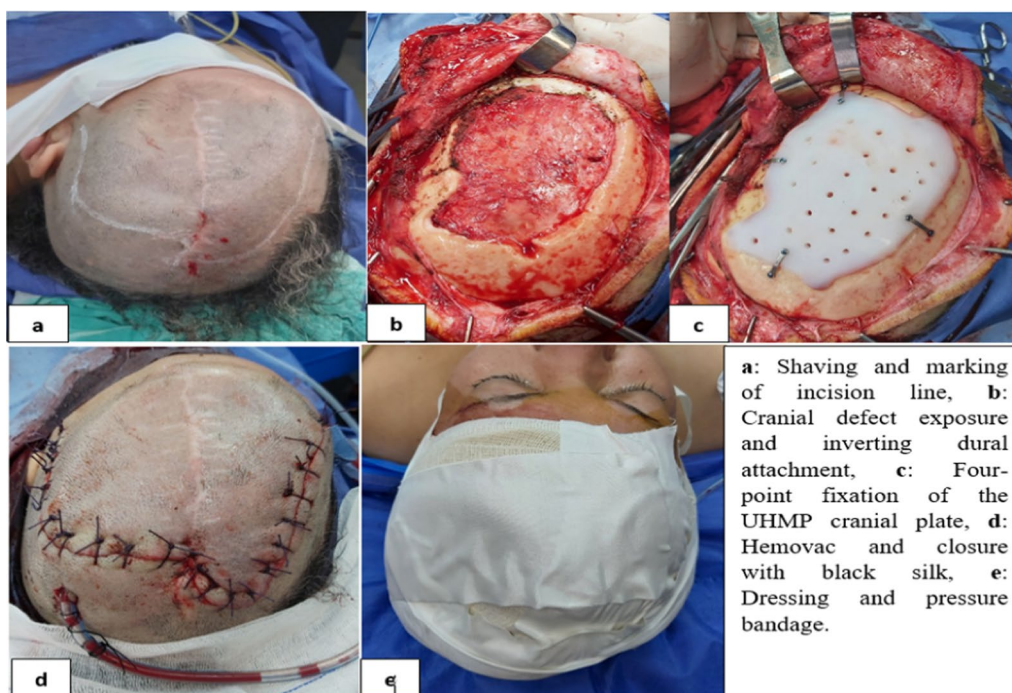


Fig. 3 A case with delayed cranioplasty after traumatic bone comminution

Postoperative care

All patients were maintained under double antibiotic coverage for a minimum of 10 days postoperatively,

together with appropriate analgesia and anticonvulsant medication. The hemovac drain and compression bandage were removed within 24–48 h. Patients were

then advised to apply antimicrobial cream for the first 3 days, followed by healing and anti-inflammatory ointments until staples/suture removal after 14 days.

Postoperative analysis

Follow-up protocol of all patients was done immediately postoperative, at three months, and again at six months. Primary assessment for the overall complications (infection, wound breakdown, hematoma, and CSF leakage) or implant failure requiring reoperation through clinical examination and imaging, while secondary assessment for patient or family satisfaction with the cranioplasty through a five-point Likert scale, Table 1.

Table 1 Scale of satisfaction with esthetic result

Satisfaction	Score
Dissatisfied	1
Little satisfied	2
Neutral	3
Satisfactory	4
Highly satisfied	5

Results

Demographics

Over the course of two years, 9 patients (8 males and 1 female; mean age 35.3 years) underwent cranial reconstruction using UHMWP patient-specific cranial plates due to defects arising from trauma—5 patients, as shown in Fig. 4, and various benign and malignant tumors—4 cases, as shown in Fig. 5. All procedures were performed under general anesthesia. The defect was in the parietal area in 33.3% of cases, while the rest represented equally in the frontoparietal, the temporoparietal and in the frontotemporoparietal areas with 22.2%. One of the patients received radiotherapy prior and chemotherapy after, while two patients had chemo- and radiotherapy sessions after, respectively. Results are summarized in Table 2.

Timing of cranioplasty

Eight patients had staged procedures, two of which patients had titanium meshes fitted before the UHMWP was finally implanted and two had their native bone left after hematoma evacuation in compound depressed fracture cases. The remaining three patients received no reconstruction attempts after their initial craniectomy procedures. The mean time interval between the initial craniectomy and final UHMWP cranioplasty was 16 months (range 7–60 months). One patient underwent a

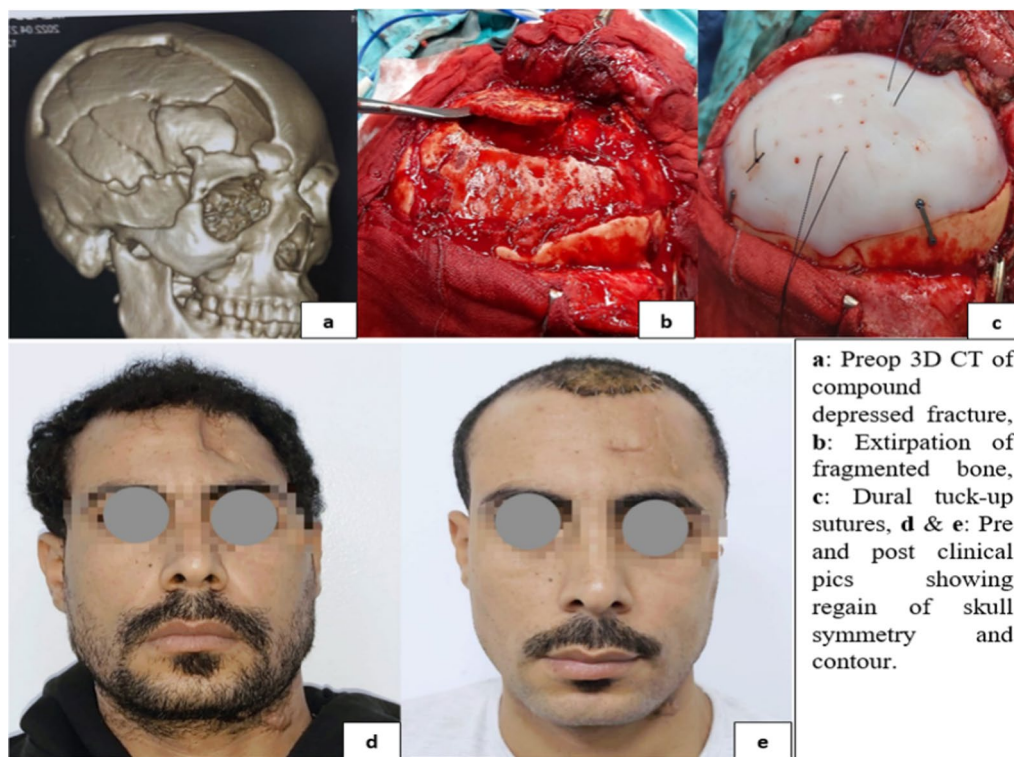


Fig. 4 A case of post traumatic compound depressed fracture with synthetic reconstruction

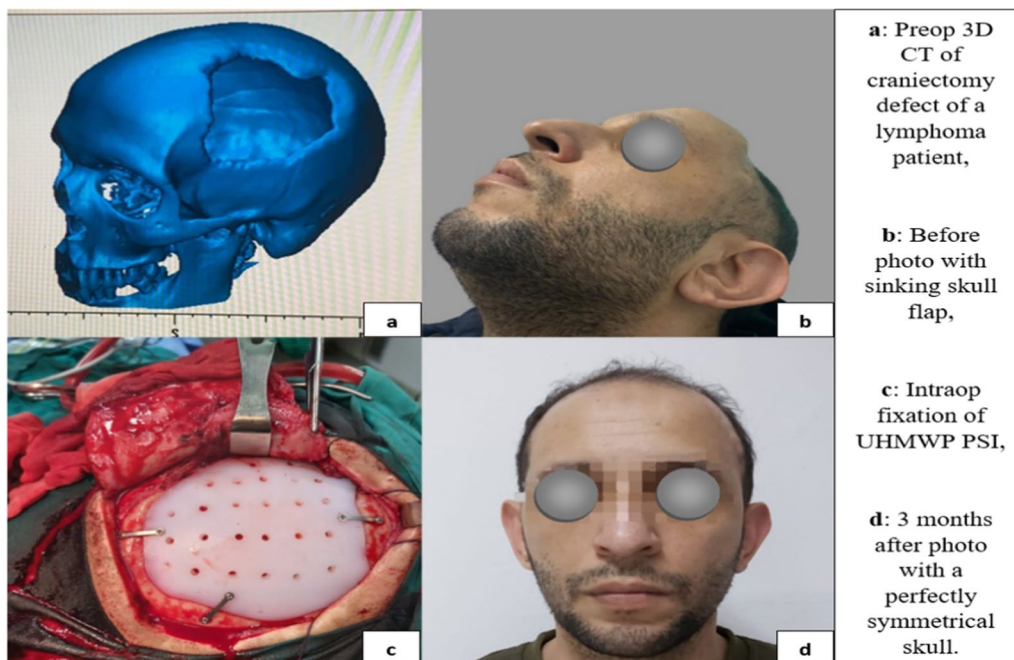


Fig. 5 A case of delayed cranioplasty post craniectomy for a lymphoma patient

single-stage immediate resection—reconstruction of his osteomyelitic necrotic infiltrated by a scalp squamous cell carcinoma (SCC).

Overall complications

Postoperative nonsurgical sequelae were observed in three patients. The first patient had a nonoperative seroma where the neurosurgeon decided to treat it conservatively with dehydrating measures and mild compression until the next consultation. The collection resolved and the patient was free of symptoms 15.5 months after the intervention.

The second sequela was observed in the scalp SCC patient. This 60-year-old patient had a very lengthy operation involving three specialties, namely the neurosurgery and maxillofacial surgery teams for the cranial resection and reconstruction, respectively, and the plastic surgery team for the soft tissue reconstruction through an anterolateral thigh free flap. Postoperatively, the patient suffered dehiscence and cutaneous necrosis of the distal margin of the flap which was suspected of tumor cell infiltration. Shortly after the patient was investigated and distant metastasis was observed. However, this did not necessitate plate removal and the patient was referred to chemotherapy before revisional soft tissue surgery.

The third and final sequela was a subgaleal hematoma (SGH) that was aspirated (≈ 60 cc) locally and the scalp swelling subsided. However, the swelling recurred within a few days and the SGH was aspirated once more (≈ 80

cc), and the scalp was fixed by compression with an elastic bandage on the patient's head. The absorbed liquid from the hematoma was a sanguineous exudate. With a follow-up of six months, this patient has not had any recurrent collections, as shown in Fig. 6.

Cranial plate infection was defined as an infection of the flap transplanted during the cranioplasty procedure, that if, necessitated surgical removal of the infected flap would be termed as implant failure. None of our patients developed focal inflammatory signs, such as local swelling, redness, pus and/or low-grade fever and subsequently none required removal of the implant. Furthermore, no extra/subdural hematoma or CSF leakage were noted in this study. The mean follow-up period was 12.3 months (range 6–19 months).

Cosmetic assessment

Esthetic patient satisfaction results were evaluated in eight out of the nine patients, taking into consideration the psychological burden of carcinoma recurrence on the 60-year-old patient. Results were highly satisfactory in six patients (75%), as in Figs. 4e and 5d, satisfactory in two patients (25%), and unsatisfactory in no patients. The average satisfaction score was 4.7 (range 4–5), as in Fig. 7.

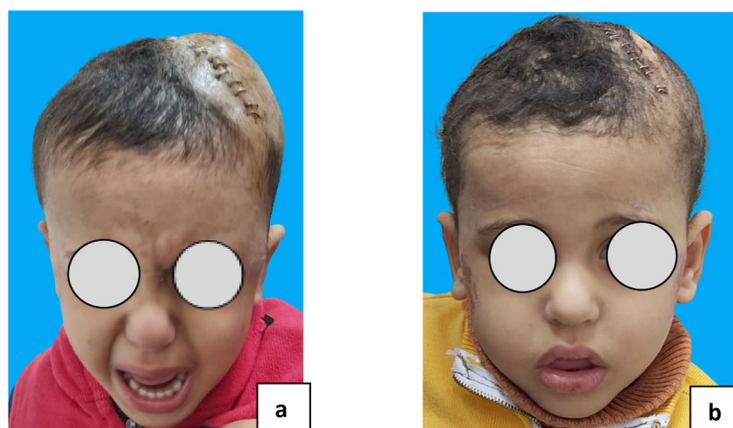
Discussion

Synthetic cranial reconstruction for significant skull defects remains a challenge for the neuro and craniofacial surgery teams alike. Most procedures are second-stage

Table 2 Patient data from case series of UHMWP PSI reconstruction

	Sex	Age (y)	Etiology	Location	Time before cranioplasty (months)	Size (cm)	Try attempts	Time of reconstruction	Complications	Follow-up (months)
1	M	34	Trauma	Temporoparietal	7	7.5	None	Delayed	None	19
2	M	37	Lymphoma	Temporoparietal	13	7.9	None	Delayed	None	15
3	M	55	Meningioma	Central parietal	60	8.5	Titanium	Delayed	Seroma	15.5
4	F	45	Trauma	Frontoparietal	20	8.7	None	Delayed	None	15
5	M	19	Meningioma	Frontoparietal	12	7.5	Titanium	Delayed	None	12.5
6	M	35	Trauma	Frontotemporoparietal	10	13.2	Bone	Delayed	None	10.5
7	M	60	SCC	Parietal	0	9	None	Single stage	ALT Flap dehiscence	8
8	M	30	Trauma	Frontotemporoparietal	14	15.1	Bone	Delayed	None	9.5
9	M	3	Trauma	Parietal	8	9.6	None	Delayed	SGH	6

M male, F female, SCC squamous cell carcinoma, ALT anterolateral thigh, SGH subgaleal hematoma, N no, Y yes



a: A three-year-old male patient with a postoperative subgaleal hematoma that was twice aspirated.
b: The patient at two weeks postoperatively before clip removal with no recurrent collection.

Fig. 6 Subgaleal hematoma collection

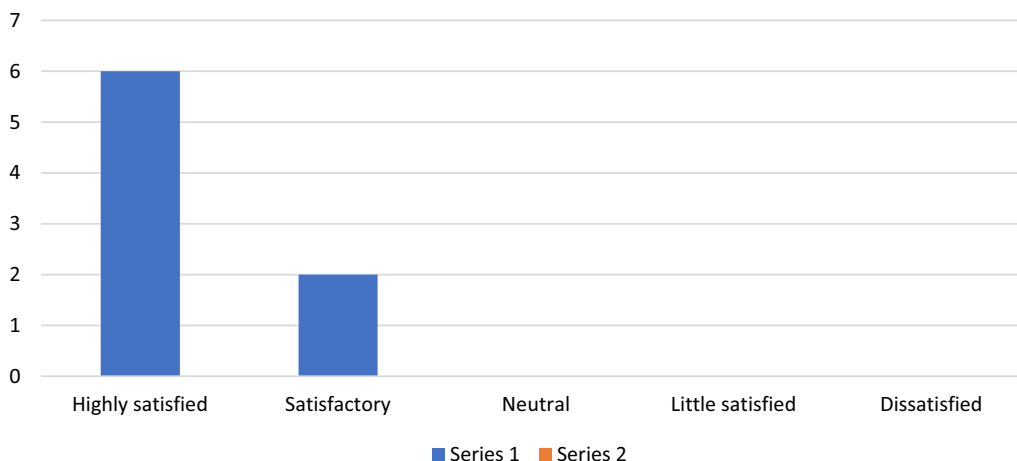


Fig. 7 Bar graph showing the results for patients' satisfaction. Among 8 patients who responded to the questionnaire, 6 were highly satisfied and 2 satisfied

surgeries for trauma or refractory intracranial hypertension cases. The shift toward synthetic alternatives, despite the native bone having several advantages, is primarily due to the risk of aseptic bone-flap resorption (ABFR) [14].

An ideal cranioplasty material must fit the cranial defect and achieve complete closure, exhibit minimal radiographic artifacts, is resistant to infection and breakage, and still comes at a low cost. Methyl methacrylate is sturdy and inexpensive but undergoes an exothermic reaction that can cause neuro hazards [1]. Titanium is readily available but is quite difficult to shape, causes radiographic artifacts, and exhibits high dehiscence with thin skin biotypes [15]. However titanium meshes can be coupled with other synthetic materials, such as

porous polyethylene, to strengthen the prosthesis [16]. Polyetheretherketone (PEEK) is currently famous for being translucent, nonmagnetic, and having lower rates of graft failure; however, it still holds a risk of postoperative inflammatory complications, which is of exceedingly high cost, and most studies promoting it are retrospective and observational [16–19]. The ideal material has yet to be discovered, but with its unique microstructure, ultra-high molecular weight polyethylene UHMWP has recently been paving its way as a solid reconstruction option for neuroprotection offering advantages like radiolucency, chemical inertness, robustness, and comfort. It does not create artifacts on imaging and does not conduct temperature. Apart from one case series in Hungary on 21 patients and another in Tokyo, Japan, on 18

patients, UHMWP hasn't been used as a cranioplasty material in any part of the world.

With CAD-CAM techniques, we operated on nine defects arising from different causes. In eight cases, delayed two-stage reconstruction was carried out and in one patient an immediate single-stage resection—reconstruction was achievable. The patients' preoperative 3D CT scans were used for virtual planning of the tumor resection or bone fragment extirpation in compound depressed fractures and designing the PSIs guided by the contralateral intact side as a template. Preoperative implant fabrication circumvents excessive intraoperative manipulations, and thus reduces operative time. However, in our experience, intraoperative adjustments to the UHMWP implants were moderately required, especially in cases where time elapsed between the digital workup and the actual operation, or patients with titanium meshes previously fitted.

In this study, cranioplasty causes were primarily due to traumatic brain injuries (55.6%) followed by meningioma and other pathologies (44%). This is similar to the synthetic cranial reconstruction patient population found by Brandicourt et al. [20]. As is known, one of the main disadvantages of alloplastic materials is that of postoperative complications and eventually implant failure. Within a follow-up range of 12.3 months, one patient developed a postoperative seroma that was managed conservatively without any surgical intervention until it subsided completely, and the patient's family were satisfied with the results. Alonso-Rodriguez et al. [16] and Jalbert et al. [21] also encountered one seroma case each in their PEEK cranioplasty studies, which were similarly managed conservatively.

As for the wound breakdown witnessed in the scalp SCC eroding the underlying bone, this patient required composite hard and soft tissue resection—reconstruction. The bony resection was done using the cutting guide as per the digital plan, hard tissue rebuilt with the UHMWP PSI and finally an ALT free flap for soft tissue reconstruction in a very lengthy operation involving multiple specialties. During follow-up, focal necrosis and dehiscence was witnessed around the posterior margins of the flap which didn't seem to respond to routine maneuvers for months. The patient started chemotherapy and suffered recurrence a few months postoperatively.

The SGH patient responded well to the local tap and didn't show any signs of further collection for a period of six months. We didn't encounter any extra/subdural hematomas in our patients, and we recommend to always design the prosthesis with suture holes to pass dural tuck-up stitches whenever possible and to perform proper hemostasis before closure to minimize the risk of extradural hemorrhage later.

None of our patients during the six-month follow-up period developed infection, CSF leak, resorption, or failure of the implant. This agrees with Vitanovics et al. [22] a study utilizing UHMWP in 21 cranial patients and Kobayashi et al. [23] a study on 18 patients in Tokyo, Japan. Both these studies also showed zero infection rate with none experiencing implant failure or the need for reoperation. This is promising as these complications are common with other synthetic alternatives including PEEK with a 13% infection rate and 12.5% implant removal rate among 40 patients [17] while titanium demonstrated 29% complication rate in 127 cranioplasties [24].

This is the first study utilizing the use of UHMWP in cranioplasty in Egypt and the middle east. However, although this study was limited by its small sample size (only nine patients), with a mean follow-up period of just 12.3 months, our results suggest that the use of prefabricated UHMWP implants provides very acceptable cosmetic results with less complications rates than other methods of cranioplasty and we encourage further research work on the topic.

Conclusions

UHMWP is a valid alternative to other synthetic cranioplasty materials in terms of excellent cosmesis and less complication rates with most postoperative sequelae being mild and responsive to conservative measures. Proper preoperative planning is important, and we recommend further prospective studies including larger sample sizes to evaluate long-term results.

Abbreviations

PMMA	Polymethyl methacrylate
UHMWP	Ultra-high molecular weight polyethylene
PSI	Patient-specific implant
CSF	Cerebrospinal fluid
CAD-CAM	Computer-aided design—computer-aided manufacturing
FDA	Food and Drug Administration
ISO	International Organization for Standardization
CT	Computed tomography
DICOM	Digital imaging and communications in medicine
STL	Standard Tessellation Language
3D	Three-dimensional
SGH	Subgaleal hematoma
PEEK	Polyether ether ketone
SCC	Squamous cell carcinoma
ALT	Anterolateral thigh

Acknowledgements

Not applicable.

Author contributions

MK is the principal investigator and responsible for data collection and follow-up of patients. Designing the PSIs and the reconstruction part in the OR. Writing of the manuscript. MS is the senior supervisor and responsible for the study design. Setting the principle for CAD-CAM designs. AK generation of treatment plans and outcome assessment during follow-up of patients. MA is the principal neurosurgeon in the study and follow-up of patients. Revision of manuscript.

Funding

This research did not receive any specific grant from funding agencies in the public, commercial, or not-for-profit sectors. This research is self-funded by the corresponding author.

Data availability

The database used and/or analyzed during the current study are available from the corresponding author on reasonable request.

Declarations**Ethics approval and consent to participate**

This research received institutional review board approval from the Ethics committee of scientific research, Faculty of Dentistry-Cairo University (Number: 6-11-21).

Consent for publication

Written informed consent was obtained from the patients for publication of this case series and any accompanying images and radiographs on condition of anonymity.

Competing interests

All the authors declare no known competing financial interests or personal relationships that could have appeared to influence the work reported in this paper.

Received: 5 May 2023 Accepted: 6 August 2023

Published online: 25 October 2023

References

- Shah AM, Jung H, Skirboll S. Materials used in cranioplasty: a history and analysis. *Neurosurg Focus*. 2014;36(4):E19.
- Prolo DJ. Cranial defect & cranioplasty. *Clin Neurosurg*. 1996;275:2783–95.
- Abd Al Ratha G, Hamandi Y. The efficacy of monomeric acrylic in cranioplasty surgery five-year follow-up. *Iraqi Natl J Med*. 2021;3(2):53–65.
- Goldstein JA, Paliga JT, Bartlett SP. Cranioplasty: indications and advances. *Curr Opin Otolaryngol Head Neck Surg*. 2013;21(4):400–9.
- Mahapure KS, Murray DJ. The historical timeline of cranioplasty. *J Plast Reconstr Aesthet Surg*. 2021;74(3):632–3.
- Hussain M, et al. Ultra-high-molecular-weight-polyethylene (UHMWPE) as a promising polymer material for biomedical applications: a concise review. *Polymers (Basel)*. 2020;12(2):323.
- Macuvele DLP, et al. Advances in ultra high molecular weight polyethylene/hydroxyapatite composites for biomedical applications: a brief review. *Mater Sci Eng C Mater Biol Appl*. 2017;76:1248–62.
- Oishi T, et al. Cosmetic and neuroprotective placement of custom-made ultra-high-molecular-weight polyethylene cranial plate (SKULPIO) in single-step surgery: technical note and case report. *World Neurosurg*. 2019;130:187–91.
- Maksimkin AV, et al. Ultra-high molecular weight polyethylene/titanium-hybrid implant for bone-defect replacement. *Materials (Basel)*. 2020;13(13):3010.
- Sobieraj MC, Rimnac CM. Ultra high molecular weight polyethylene: mechanics, morphology, and clinical behavior. *J Mech Behav Biomed Mater*. 2009;2(5):433–43.
- Brach Del Prever EM, et al. UHMWPE for arthroplasty: past or future? *J Orthop Traumatol*. 2009;10(1):1–8.
- Jonášová L, et al. Biomimetic apatite formation on chemically treated titanium. *Biomaterials*. 2004;25(7–8):1187–94.
- Anderson BC, et al. Al–Cu–Fe quasicrystal/ultra-high molecular weight polyethylene composites as biomaterials for acetabular cup prosthetics. *Biomaterials*. 2002;23(8):1761–8.
- van de Vijfeijken S, et al. Factors related to failure of autologous cranial reconstructions after decompressive craniectomy. *J Craniomaxillofac Surg*. 2019;47(9):1420–5.
- Aydin S, et al. Cranioplasty: review of materials and techniques. *J Neurosci Rural Pract*. 2011;2(2):162–7.
- Alonso-Rodriguez E, et al. Polyetheretherketone custom-made implants for craniofacial defects: report of 14 cases and review of the literature. *J Craniomaxillofac Surg*. 2015;43(7):1232–8.
- Jonkergouw J, et al. Outcome in patient-specific PEEK cranioplasty: a two-center cohort study of 40 implants. *J Craniomaxillofac Surg*. 2016;44(9):1266–72.
- Punchak M, et al. Outcomes following polyetheretherketone (PEEK) cranioplasty: systematic review and meta-analysis. *J Clin Neurosci*. 2017;41:30–5.
- Murnan EJ, Christensen BJ. Risk factors for postoperative inflammatory complications after maxillofacial reconstruction using polyether-etherketone implants. *J Oral Maxillofac Surg*. 2021;79(3):696.e1-696.e7.
- Brandicourt P, et al. Reconstruction of cranial vault defect with polyetheretherketone implants. *World Neurosurg*. 2017;105:783–9.
- Jalbert F, et al. One-step primary reconstruction for complex craniofacial resection with PEEK custom-made implants. *J Cranio-Maxillofac Surg*. 2014;42(2):141–8.
- Vitanovics D, et al. Tailored cranioplasty using CAD–CAM technology. *Ideggyogy Sz*. 2014;67(11–12):390–6.
- Kobayashi K, et al. Ultra-high-molecular-weight polyethylene (UHMWPE) wing method for strong cranioplasty. *Neurol Med Chir (Tokyo)*. 2021;61(9):549–56.
- Wiggins A, et al. Cranioplasty with custom-made titanium plates-14 years experience. *Neurosurgery*. 2013;72(2):248–56.

Publisher's Note

Springer Nature remains neutral with regard to jurisdictional claims in published maps and institutional affiliations.

Submit your manuscript to a SpringerOpen[®] journal and benefit from:

- Convenient online submission
- Rigorous peer review
- Open access: articles freely available online
- High visibility within the field
- Retaining the copyright to your article

Submit your next manuscript at ► [springeropen.com](https://www.springeropen.com)